

Teratogenic effects of di-(2-ethylhexyl)-phthalate (DEHP) on Survival, Morphology and Skeleton System of Mice Fetuses

EL-Balshy, R. M.¹, Ibrahim, S.A², Award, M.H³, El- Daly, A.A⁴, Iskandar, M.K.⁵

^{1, 2, 3, 4, 5}Department of Zoology- Faculty of Science- Benha University-Benha- Egypt

Abstract: *The present study dealt with the effects of di-(2-ethylhexyl)-phthalate (DEHP) on the skeletal system of the prenatal fetuses of 20th day of gestation. DEHP treatment caused fetal mortality, retarded weight, length and ossification of some bones and shortness of others. Skull, vertebrae, sternum, girdles and limbs were the main affected by DEHP.*

Keywords: Skeletal system –di-(2-ethylhexyl) phthalate – Teratogenesis – Malformation.

1. Introduction

Di-(2-ethylhexyl)-phthalate (DEHP) is one of a variety of plasticizers used in the production of polyvinyl chloride plastics, polyvinyl acetate, rubbers, cellulose plastics, and polyurethane resins which is one of a variety of plasticizers used in the production of polyvinyl chloride plastics, polyvinyl acetate, rubbers, cellulose plastics, and polyurethane resins (Hauser & Calafat 2005).

DEHP can be used as a polymer and a no polymer. As a polymer, DEHP has been primarily used as plasticizer in plastics production (97% of all DEHP) due to its suitable properties and the low cost. It has additional uses in the creation of polyvinyl chloride (PVC), polyvinyl acetate, rubbers, cellulose plastics and polyurethane. Its use in medical devices (medical tubing and IV bags) and industrial/commercial products accounted for 25% and 45% of the overall consumption, respectively (SCENIHR, 2007).

As a non-polymer, DEHP has been used in the formulation and industrial use of sealants, adhesives, paints, lacquers, printing inks, ceramics and it also used as a hydraulic fluid and as a dielectric fluid in capacitors, and these uses constituted less than 3 to 5% of the national use of DEHP (ATSDR, 2002). DEHP hydrolyzes to mono-ethylhexyl phthalate (MEHP) and subsequently to phthalate salts and the released alcohol is susceptible to oxidation to the aldehyde and carboxylic acid according to (Lorz *et al.*, 2005).

DEHP that absorbed following oral exposure were rapidly metabolized to MEHP by intestinal contents, pancreatic lipases, and/or other esterase are at low dose exposures. Intact DEHP was systemically available following high dose exposures. DEHP that absorbed and metabolized were transported to target tissues such as the liver, kidneys, and fat and were oxidative metabolized to approximately 15 to 20 metabolites. The metabolites of DEHP were then conjugated and eliminated in manner depend on a species in the urine and feces. Distribution to the tissues was short-lived and DEHP and or metabolites did not accumulate. DEHP and its metabolites also distributed across the placenta and into the milk of pregnant dams. This resulted in residues in fetal and neonatal tissues (Carlson, 2010).

Fetuses and infants who are believed to be one of the most sensitive populations to environment chemicals (Hollady & Smialowicz, 2000) can be maternally exposed to DEHP. In fact, DEHP, have been detectable in human cord blood and maternal plasma (Latini *et al.*, 2003). In addition, MEHP has been found in human breast milk (Main *et al.*, 2006), and in infant (Mortensen *et al.*, 2005 and Sorensen, 2006). The previous studies have suggested that maternal exposure to phthalates during fetal and neonatal periods may cause developmental toxicities in offspring.

Numerous studies have shown that DEHP is capable of crossing the placental barrier and can be toxic to the developing fetuses (Foster, 2006). High doses of DEHP fed during certain days or through gestation resulted in a range of embryo toxic and Teratogenic effects. Single oral doses administered to pregnant mice resulted in dose and time-dependent adverse outcomes in the fetuses, including a marked decrease in litter size and malformation in all live fetuses (Foster, 2006).

The present work aims to investigate the possible teratogenicity effects of DEHP on mice fetuses. The work focused on the survival, morphological and Osteological alterations of the fetuses of mice.

2. Material and Methods

For the present study, Bi-(2-ethylhexyl) phthalate (DEHP) was obtained from the Egyptian company "LOBACHEME", Cairo, with a chemical formula C₂₄H₃₈O₄ and Molar mass 390.56 g·mol⁻¹. DEHP was dissolved in corn oil. The oral LD₅₀ values in mice generally exceeded 30g/kg (Woodward *et al.*, 1986). The low dose of LD₅₀ is (0.0012ml/kg) and the high dose of LD₅₀ is (0.00253ml/kg). The pregnant mice were divided into five groups; Control (c) group and four DEHP - treated groups (G1; G2; G3 & G4).

Pure strain of mice (virgin male and females of Albino mice); *Mus musculus*, provided from Theodor Bilharz research institute; El Nile road, Warrak El Hadar, Embaba, Egypt were used for experimentation. The adult virgin females of approximately age 2-3 month were selected, Each three of them were kept with one adult male in one

cage overnight, In the next morning pregnancy was assured by the presence of vaginal plug, Each pregnant female was kept in a separate cage. In case of absence of the vaginal plug, a drop from the vaginal contents was prepared and examined for the presence of the spermatozoa, their presence was taken as a sign of copulation, these female were considered to be at the first day of pregnancy (Billet & Wild, 1975 and McClain & Becker, 1975).

The used mice (pregnant female) were arranged in five groups; the control group (c) was consist of group of Pregnant female treated by corn oil; G1 was consist of group of pregnant female treated by low dose (LD) of LD₅₀(0.0012ml/kg) of DEHP dissolved in corn oil at (1st -7th) day of Pregnancy; G2 was consist of group of pregnant female treated by high dose(HD) of LD₅₀(0.00253ml/kg) of DEHP dissolved in corn oil at (1st -7th) day of Pregnancy; G3 was consist of group of pregnant female treated by HD of LD₅₀ of DEHP dissolved in corn oil at (7th -20th) day of Pregnancy; G4 was consist of group of pregnant female treated by HD of LD₅₀ of DEHP dissolved in corn oil at (7th -20th) day of Pregnancy. At the 20th day of gestation, the uteri were removed by cesarean sections. For each mother, the number of fetal swelling in each horn, living and dead fetuses and early of late resorptions were recorded. Early and late resorptions were discerned according to their size. For morphological studies, fetuses either living or dead were counted, weighed and measured then morphologically examined for any external malformation. For studying the skeletal malformations, Fresh fetuses were skinned then they fixed in 95% ethanol for 5 days, then they putted in acetone for 2 days. After this, the fetuses were stained for 3 days in 20 ml freshly prepared staining solution at 4° C. The staining solution is consisted of: (1 ml 0.1% Alizarin Red-S in 95% ethanol + 1 ml 0.3% Alcian blue 8Gs in 70% ethanol + 1 ml glacial acetic acid + 17 ml 70% ethanol)(Mc Gee- Rusell, 1958 and Falkeholm *et al.*,2006).

After the staining process was completed, the fetuses were washed with tap water, and then the fetuses were putted in ascending series of glycerol and 1% aqueous KOH solution and then preserved in 100% glycerin for examination and photography.

3. Results

3.1. External Morphology

In the present work, the external morphological examination indicated that di-(2-ethylhexyl)-phthalate (DEHP) causes growth retardation for fetuses (20th day of gestation) which is indicated by the reduction of fetal body weight and length (Table 1&2 and Fig. 1). The reduction in the weight of fetuses maternally treated with DEHP in comparison with the control with oil (1.9±0.20) was 1.7±0.13, 1.5±0.11, 1.6±0.12 and 1.2±0.21 for G1, G2, G3, and G4 respectively. This result indicated that the most decrease in the weight of fetuses maternally treated with DEHP is in the group G3 that treated with high dose of DEHP from 7-20 days of gestation (Fig.1).The mean fetal length of fetuses maternally treated with DEHP was significantly decreased. It was 1.7±0.13, 1.5±0.11, 1.6±0.12 and 1.2±0.21 for G1, G2, G3 and G4 respectively on compared to the control (1.9±0.20) (Fig.2).

Examination of the maternally treated fetuses showed dark red patches (haematoma) scattered on the different parts of the body (fig.3)

The present investigation indicated that all treated groups produced fetuses without any alteration in the external body shape. However, some cases were recorded in “G2” and “G4” which they showed deformed prenatal fetuses (Fig. 3).

3.2 Fetal mortality

The number of fetuses at 20th day of gestation is generally increased in all the DEHP treated groups compared with the control one (Table3).The percent of change of the total fetuses of the treated group to those of the control group was found to be 63.6% at the group G1, 45.5% at the group G2, 75.0%at the group G3 and 40.9%at the group G4. In addition, the percentage of change of a live fetuses in comparison with the a live fetuses of the control was 36.4%, 54.5%, 25.0% and 59% in case of G1, G2, G3 and G4 respectively.(Table 3)show also four dead fetuses out of total 32 in G1, seven dead fetuses out of total 27 in G2, five dead fetuses out of total 38 in G3 and eight dead fetuses out of total 26 in G4. This result indicated that the more effective fetuses are in the group G4 that treated with high dose of DEHP from 7-20 days of gestation (Table 3).

Table 1: Effect of DEHP on the body weight of 20th -days-old fetuses.

s	C	G1	G2	G3	G4
1	1.32	1.11	0.82	1.22	1.12
2	1.31	1.05	0.8	1.14	1.08
3	1.4	1.3	1.3	1.14	0.98
4	1.3	1.1	0.98	0.98	0.89
5	1.32	0.95	1.05	0.97	0.88
6	1.2	1.0	1.2	0.88	0.95
7	1.3	1.1	0.9	1.21	0.82
Mean ±SD	1.3±0.1	1.1±0.1	1±0.2	1.1±0.1	0.9±0.1
SR	0.04	0.04	0.07	0.04	0.04

Table 2: Effect of DEHP on the body length of 20th days-old fetuses

NO	C	G1	G2	G3	G4
1	2.01	1.88	1.32	1.75	1.32
2	1.75	1.68	1.56	1.45	1.22
3	1.85	1.75	1.66	1.5	1.54
4	1.65	1.65	1.58	1.6	1.22
5	1.98	1.49	1.58	1.7	0.98
6	2.10	1.54	1.54	1.65	0.98
7	2.21	1.68	1.58	1.75	1.01
Mean±SD	1.9±0.20	1.7±0.13	1.5±0.11	1.6±0.12	1.2±0.21
SR	0.08	0.05	0.04	0.046	0.08

Table 3: Effect of DEHP on the percent of change of total fetuses and a live fetus in case of treated groups compared with the control

	Total NO. of fetuses	Mean SD	%change from control	% change from alive
Control	44	6.2	0.00	0.00
Alive	44	62		
Dead	-	-		
G1	32	4.6	636%	36.4%
Alive	28	3.9		
Dead	4	0.9		
G2	27	3.9	45.5%	54.5%
Alive	20	2.9		
Dead	7			
G3	38	5.6	75.0%	25%
Alive	33	4.7		
Dead	5	0.8		
G4	26	3.8	40.9%	59%
Alive	18	2.4		
Dead	8	1.00		

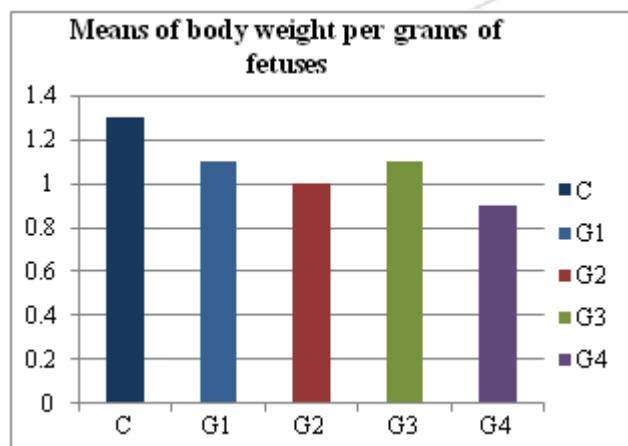


Figure 1: Histogram showing the mean change in the body weight of the fetuses of 20th day of gestation of the control and treated groups (G1&G2&G3 and G4).

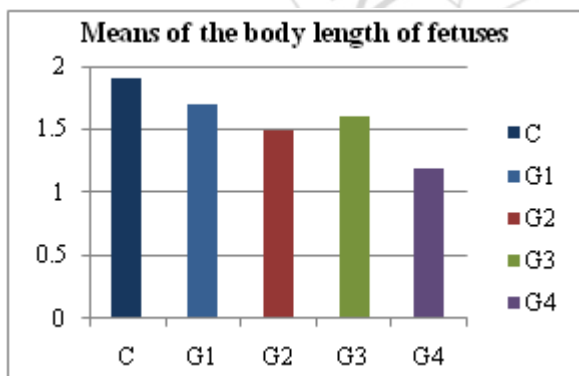


Figure 2: Histogram showing the mean change in the body length of the fetuses of 20th days of gestation of the control and the treated groups (G1&G2&G3 and G4).

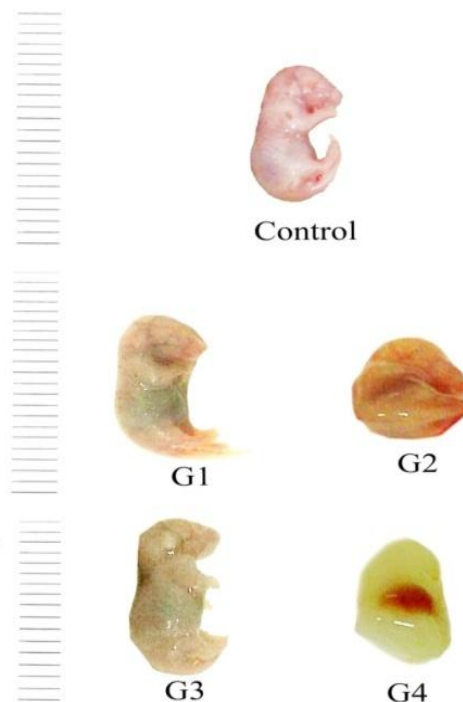


Figure 3: Photographs of 20th day of gestation showing: control and four Di (2-ethyhexyl)-phthalate (DEHP)- treated groups (G1, G2, G3& G4).

3.3 Osteological observations

Generally, the skeletal system of the Albino mouse consists of two main structures; the axial skeleton and appendicular skeleton. The axial skeleton comprises bones of the skull, vertebral column, ribs and sternum while the appendicular skeleton consists of bones of pectoral girdle and fore limbs and pelvic girdle and hind limbs (Fig. 4).

Osteological malformation of 20th day fetuses indicated that treatment of mother with different dose of DEHP caused several undesirable effects ranging from moderate to severe malformations. These effects include both chondrogenesis and osteogenesis that take place in the formation of the skeletal system of the animal. In addition, the treatment of pregnant mice with different doses of DEHP caused a considerable delay in the development of bones of fetuses (Fig. 4).

3.4 Axial Skeleton

3.4.1 The Skull

At 20th day of gestation, the skull components of control fetuses showed more or less complete ossification. However, the tympanic and squamosal regions are partially ossified. The premaxilla is fused with the nasal and maxillary bones. The frontal bones consist of two halves surrounding the anterior fontanella. At the base of the cranium the ethmoid and presphenoid bones are well developed in one plane. The mandible is ossified with a slightly angulated ramus (Fig. 5-7).

Examination of the skull of fetuses maternally treated with different doses of DEHP showed incomplete ossification of the nasal, frontal, supraoccipital, parietal, interparietal, zygomatic process of squamosal, tympanic bulla, squamosal, periotic, supraoccipital, palatine, pterygoid and ethmoid bones i.e. the skull stain blue with alcian blue indicating that they are cartilaginous in nature and confirmed the delay in development of such bones. This effect progressed directly with the increment of the used dose (Figs. 4-10). The most evident decrement was deposition of bone material that starts with the control with oil, progresses with first group then third group then second group and reached its final effects in the fourth group. In the skull of the fourth group all the components of the skull stained bile blue with alcian blue indicating that they severe lack ossification in all of its components. In addition, the skull of "G4" showed deformed in its shape due to high dose of DEHP. The bones of the lower jaw showed moderate ossification in fetuses of all treated groups (Fig.5-6).

3.4.2 The vertebral column

The vertebral column of control fetuses showed more or less ossified vertebrae which are represented by 7 cervical, 12 thoracic, 7 lumbar, 4 sacral and 10 caudal vertebrae (Fig.7).

Examination of the vertebral column of fetuses maternally treated with different doses of DEHP revealed that the atlas and axis vertebrae well not well ossified. Vertebrae of "G1" and "G3" showed no alteration from the control with the exception of the caudal vertebrae which showed a complete non-ossification. Most of the examined fetuses of "G2" and "G4" showed severe lack of ossification in their cervical, thoracic, and lumbar. Moreover, sacral and caudal vertebrae were completely non-ossified (Fig. 7).

3.4.3 Ribs

The control fetuses possess 13 pairs of rib with well ossified vertebral portions, while the sternal portions of ribs appeared more or less cartilaginous in nature (Fig. 4). The ribs of fetuses in all treated groups were shorter than the control one. The ribs of the second group and fourth group were curled and twisted shapes ribs. The length of ribs of fetuses of the fourth group was the shorter than the length of ribs of fetuses of the second group. The cartilaginous portion of the ribs exhibited less blue coloration than the normal referred to reduction in its chondrification (Fig. 4).

3.4.4 Sternebrae

The control fetuses possess 6 good ossified sternae and the last one of them is the xiphisternum. The sternae of fetuses maternally treated with different doses of DEHP were shorter than the control group. The most affected sternae were observed in the second and the fourth group that treated with high dose of DEHP (Fig. 8).

3.5 The appendicular skeleton

3.5.1 The pectoral girdle and fore limb

The pectoral girdle of the control fetuses of 20th day of gestation consists of a well ossified scapula and clavicle, stained well with alizarin red "s", while the suprascapula still cartilaginous in nature and stained with alcian blue (Fig. 9). The fore limb of the control fetuses of 20th day of gestation

consists of ossified humerus, radius, and ulna, phalanges with five digits and cartilaginous carpalia and metacarpalia. The components of the pectoral girdle and fore limb of fetuses obtained from mothers treated with different doses of DEHP are manifested by reduction in size and the degree of ossification in reference to the control (Fig.9). At high dose level of DEHP pectoral girdle and fore limbs of all examined fetuses of "G2" and "G4" showed severe lack of ossification (Fig.9).

3.5.2 The pelvic girdle and hind limb

The pelvic girdle of the control fetuses of 20th day of gestation consists of three well ossified bones; ilium, ischium and pubis. The pubic symphysis remains cartilaginous in nature. The hind limb of the normal fetuses consists of well ossified bones; femur, tibia and fibula, a series of phalanges in the four digits and cartilaginous tarsals and metatarsals (Fig.10). The pelvic girdle and hind limb of fetuses of 20th day of gestation obtained from mothers treated with different doses of DEHP showed that the degree of ossification of ilium, ischium, pubis, femur, tibia and fibula and a series of phalanges was affected especially at the high dose level of DEHP. The ilium, ischium, pubis, femur, tibia and fibula and a series of phalanges of the fetuses of the fourth group showed severe lack of ossification were absent. The degree of the chondrification of the pubic symphysis, tarsals and metatarsals was also affected especially at the high dose level of DEHP. The length of the components of the pelvic girdle and fore limb was shorter than the control (Fig.10).

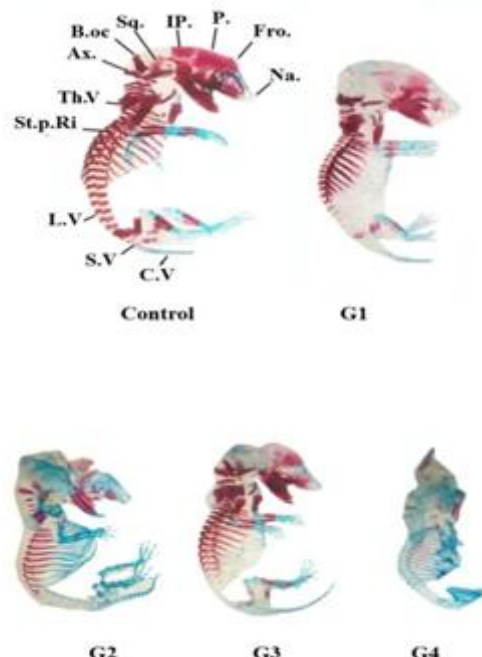


Figure 4: Photographs of lateral view of the skeletal system of 20th day of gestation showing: four DEHP treated group (G1, G2 and, G3& G4).

Abbreviations

N.: Nasal; Fro. Frontal; P.: Parietal; IP.: Interparietal; Sq: Squamosal; B.oc : Basioccipital; Ax.: Axis; T.V: Thoracic vertebrae; St.p.Ri: Sternal portion of ribs; L.V: Lumbar vertebrae; S.V: Sacral vertebrae; C.V: Cervical vertebrae

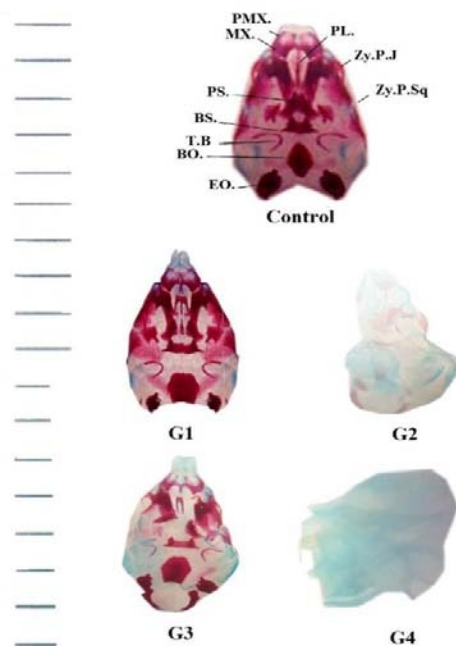


Figure 5: Photographs of the lateral view of the skull of 20th day of gestation fetuses showing: Control and four DEHP- treated groups (G1, G2, and G3& G4).

Abbreviations:

MX: Maxilla; PMX: Premaxilla; PL.: Palatine; BO: Basioccipital; PS.: Presphenoid; BS. : Basisphenoid; T.B.: Tympanic bulla; Zy.P.J: Zygomatic process of jugal; Zy.P.Sq: Zygomatic process of squamosal; EO. : Exoccipital.

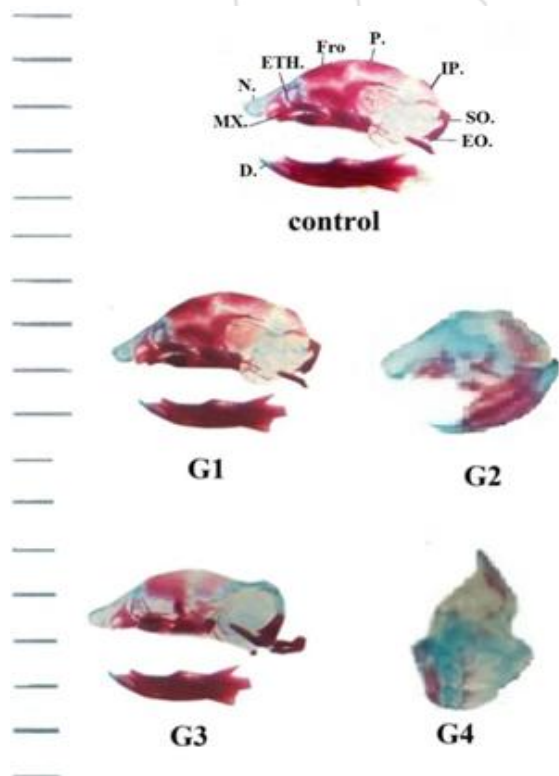


Figure 6: Photographs of the ventral view of the skull of 20th day of gestation showing: control and four DEHP- treated groups (G1, G2, and G3& G4).

Abbreviations:

D.: Dentary; MX: Maxilla; N.: Nasal; ETH: Ethmoid; Fr.: Frontal; P.: Parietal; IP.: Interparietal; SO.: Supraoccipital; EO. : Exoccipital.

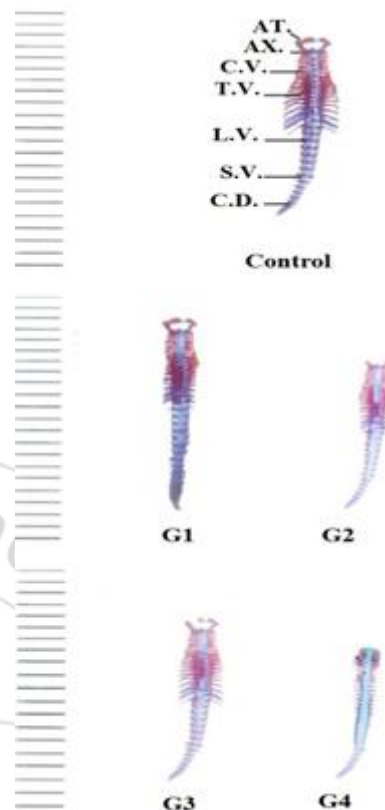


Figure 7: Photographs of the ventral view of the vertebral column of 20th day of gestation Showing: control and four DEHP- treated groups (G1, G2, and G3& G4)

Abbreviations:

AT. : Atlas; AX. : Axis; C.V.: Cervical vertebrae; T.V.: Thoracic vertebrae; L.V.: Lumbar vertebrae; SV: Sacral vertebrae; C.D.: Caudal vertebrae.

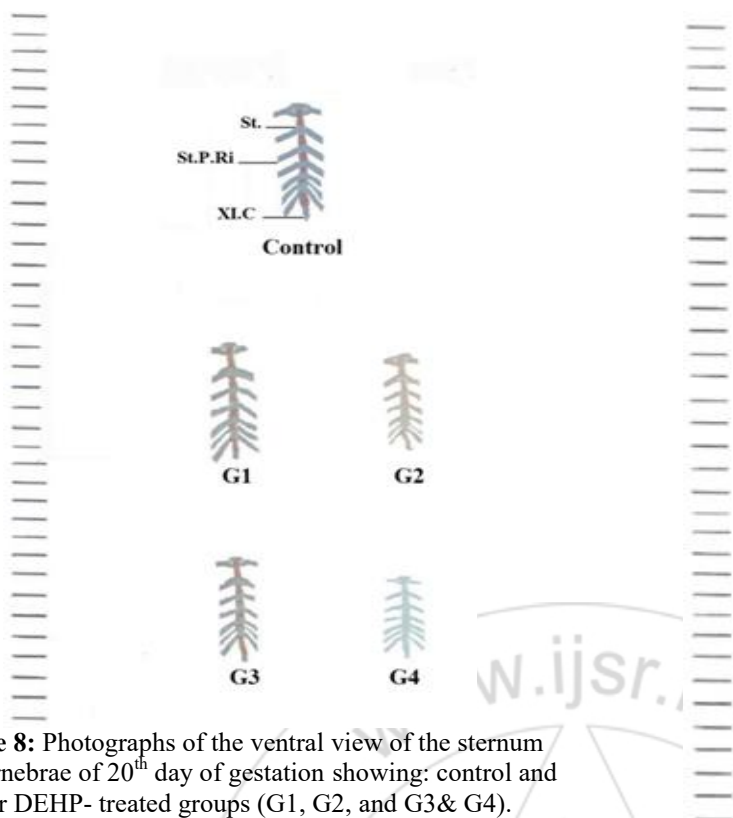


Figure 8: Photographs of the ventral view of the sternum and sternebrae of 20th day of gestation showing: control and four DEHP- treated groups (G1, G2, and G3& G4).

Abbreviations:

ST: Sternebrae; ST.P.Ri: Sternal portion of ribs; XLC: Xiphoid cartilage.

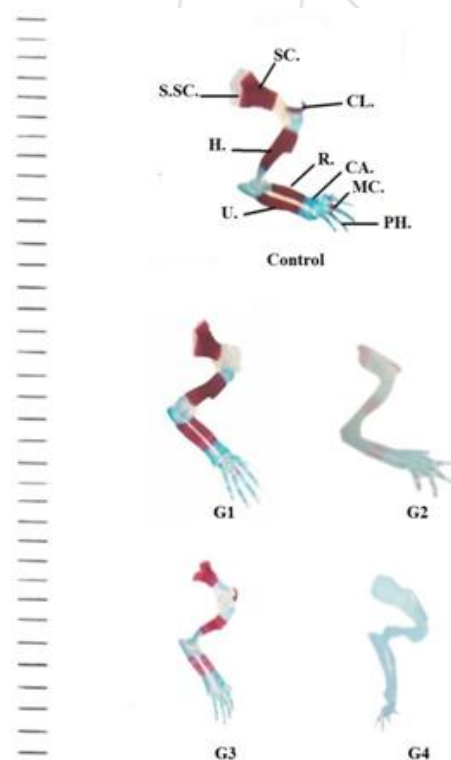


Figure 9: Photographs of lateral view of the pectoral girdle and fore limb of 20th day of gestation of control and four DEHP- treated groups (G1, G2 and G3& G4).

Abbreviations: S.SC: Supra-scapula; SC.: Scapula; CL.: Clavicle; H.: Humerus; R.: Radius. Ulna; CA: Carpals; MC: Metacarpalia; PH.: Phalanges.

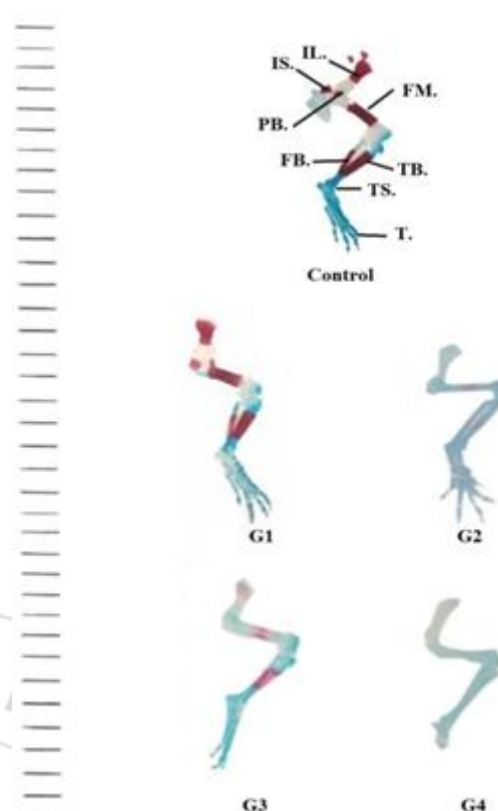


Figure 10: Photographs of lateral view of the pelvic girdle and hind limb of 20th day of gestation showing: control and four DEHP- treated groups (G1, G2, and G3& G4).

Abbreviations:

IL: Ilium; IS. : Ischium; PB: Pubis; FM.: Femur; FB. : Fibula; TB: Tibia; TS: Tarsalia; T: Toes.

4. Discussion

Di-(2-ethylhexyl) - phthalate (DEHP) is widely spread environmental contaminants because of their use in plastics and other common consumer products. Therefore, the present study was designated, in one hand, to assess the hazardous effects of some household chemical such as DEHP on nursing mice (mothers) gestation (21 days).

The household products that contain harmful chemicals as DEHP can pose serious health risks especially to mothers and their offspring. It may be metabolized in the mother's body and the toxic metabolites than pass to their developing offspring, resulting in arrange of embryo toxic and Teratogenic effects. Studies have shown that DEHP is capable of crossing from mother's body to their offspring through the placenta (Latini *et al.*, 2003) or milk (Calafat *et al.*, 2004 and Main *et al.*, 2006) and appeared in their developing offspring (Mortensen *et al.*, 2005 and Sorensen, 2006). Therefore, fetuses and infants are believed to be one of the most sensitive populations to environmental chemicals (Holladay and Smialowicz, 2000).

Assessment of health hazards arising from occupational exposure of animal or human to toxic substances in the environment has already been studied by many worker, but, the effect of DEHP on fetuses have got little attention. The present study showed that oral administration of DEHP with

the use low(0.0012ml/kg) and high dose (0 .00253ml/kg)from 1- 7 day of gestation and from 8-20 day of gestation caused toxic effects to the fetuses of 20th of gestation. These effects were observed in body weight and length of fetuses and number of alive and dead fetuses.

The present study showed that the number of live fetuses obtained from mother treated with DEHP was decreased in compared with the control. The percent of reduction was increased with the dose increment and dead fetuses were pronounced at high dose of DEHP from 7-20 days of gestation. This confirmed with **Lamb et al., 1987** that reported that exposure of mice to DEHP produced a dose-dependent decrease in the number of litters and in the numbers and the proportion of pups born alive. **Tylet al., 1988** reported that the number and percentage of resorptions, late fetal death, dead and malformed fetuses were all significantly increased, and the number of live fetuses per litter was significantly reduced at 0.1 and 0.15%. The percentage of all fetuses with malformations and the percentage of malformed fetuses per litter were significantly increased from doses of 0.05% of DEHP in mice. **Wolkowski-Tyl et al., 1984b** also studied the effect of 0, 0.025, 0.05, 0.1, or 0.15% bi(2-ethylhexyl)phthalate (equivalent to 0, 44, 91, 191, or 292 mg/kg/day, respectively) in the diet given to mice on days 0-18 of gestation. Dose-related increases in resorptions and in dead fetuses per litter were significant at doses of 0.1 and 0.15%. Significant increases in malformed fetuses per litter, with external, visceral and skeletal defects, were observed at doses of 0.15%. Studies utilizing higher oral doses (250, 500, 1000 or 2000 mg/kg) by **Shiota & Mima (1985)** and (0.05, 0.1, 0.2, 0.4 or 1.0% diet) by **Shiota and Nishimura (1982)** and **Shiota et al., (1980)** demonstrated increased numbers of fetuses with gross external malformations, including neural tube defects. The incidence of resorptions increased up to 100% in animals fed 0.4 and 1% bis(2-ethylhexyl) phthalate in their diets.

The present study showed that the fetal body weight and length of maternally treated with DEHP was less than that observed in the control. This result indicated that the most decrease in the weight of fetuses maternally treated with DEHP is in the group G4 that treated with high dose of DEHP from 7-20 days of gestation. **Tylet al., 1988** reported also significantly decrease fetal weight at 0.1 and 0.15% of DEHP in mice. **Wolkowski-Tylet al. (1984a)** reported also Dose-related decrease in fetal weight of rat treated with DEHP that was significant in all treated groups. **Tomita et al., (1982b)** reported that single administration of DEHP over 0.1 ml/kg (1/300 of LD50) on day 7 of gestation decreased the numbers and the body weight of living fetuses. **Foster, 2006 and Matsumoto et al., 2008** found that DEHP cause developmental toxicity including intrauterine death, developmental delay and structural malformations and variations. Previous animal studies have suggested that maternal exposure to phthalates during fetal and neonatal periods may cause reproductive and developmental toxicities in offspring due to their actions as endocrine disrupting chemicals, EDCs (**Kim et al., 2004 and Borchet al ., 2006**). The decrease in body weight of nursing mothers during lactation with DEHP and that off their offspring is in

agreement with other results (**Miura et al ., 2007**) found a significant decrease in the body weight.

The present study dealt with the effect of DEHP on skeletal malformations produced in mice fetuses that examined on day 20th of gestation. It has been found that DEHP in the used dose (0.0012ml/kg and 0 .00253ml/kg) caused variable deformities in some elements of the examined skeletal system and absent ossification of some parts of the components of the skeleton.

In the present work DEHP treatment "G1, G2, G3 and G4" was found to cause growth retardation and circulatory disorders in the form of hematoma in different parts of the fetal body. However DEHP doesn't cause any change in body shape of fetuses with the exception of some cases in each of "G2" and "G4". These results confirmed with that observed by **Singh et al., (1972)** that reported gross abnormalities in the treated rats as absence of tail, anophthalmia, twisted hands and legs, and hematomas. **Yagi et al., (1980)** also reported gross abnormalities included exencephaly, open eyelid, and club foot in mice that treated with 2.5 or 7.5 ml/kg of DEHP orally on days 7 or 8 of gestation respectively. Gross malformation as exencephaly, open eyelid, club foot and absent of tail in the malformed mouse fetuses maternally treated with DEHP also reported by **Tomita et al., (1982b)**.

The present results showed that DEHP delayed in development of the skull bones according to the intensity of the red coloration denoting decrease in the process of osteogenesis. The bones of the skull that revealed retardation in ossification were parietal, interparietal, zygomatic process of squamosal, tympanic bulla, squamosal, periotic, supraoccipital, palatine, pterygoid and ethmoid bones. These results coincided with that observed by other authors (**Yagi et al., 1980; Tomita et al., 1982b**) examined the effect of DEHP on ddY-Slc (SPF) mice and observed Skeletal abnormalities occurred in the skull. In the present study the shape of skull of the fourth group was different from the control and the components of the skull stained bile blue with alcian blue indicating that they were the delayed in ossification and chondrified due to the high dose treatment of fourth groups. Abnormal or incomplete skull bones were reported also by **Singh et al., (1972)** to pregnant female rats subjected to the toxicity of eight phthalic acid esters. These esters included diethyl, dimethoxyethyl, diethyl, dibutyl, diisobutyl, butyl carbobutoxymethyl, dioctyl and di-(2-ethylhexyl) phthalates.

In relation to the vertebral column, the present study revealed absence of ossification of some cervical, thoracic, lumbar, sacral and caudal vertebrae. Acute malformation was observed in cervical, thoracic, lumbar, sacral and caudal vertebrae of the fetuses of the second and the fourth groups. These results coincided with that observed by **Tomita et al., (1982b)** that reported abnormal thoracic lumbar, sacral and caudal vertebrae of mouse fetuses due to DEHP administration. This also coincided with (**Shiota & Nishimura 1982**) that reported delayed ossification, neural tube defects, and tail anomalies in mice treated with DEHP. The present study reported that the ribs and sternebrae were shorter than the control group. The

cartilaginous portion of the ribs exhibited less blue coloration than the control referred to reduction in its chondrification. The ribs of the second group and fourth group were curled and twisted shapes ribs due to high dose level. **Tomita et al., (1982b)** reported a skeletal malformation fetus that includes abnormal ribs in mouse that treated with DEHP.

In relation to the appendicular skeleton, the present study showed that the clavicle and scapula bone was shorter than the control. The degree of ossification of scapula, clavicle, humerus, radius and ulna was affected especially at the high dose level of DEHP. The ossification of scapula, clavicle, humerus, radius and ulna of the fetuses of the fourth group were absent. The degree of ossification of ilium, ischium, pubis, femur, tibia and fibula and a series of phalanges was affected especially at the high dose level of DEHP. The ossification of ilium, ischium, pubis, femur, tibia and fibula and a series of phalanges of the fetuses of the fourth group were absent. The degree of the chondrification of the pubic symphysis, tarsals and metatarsals was also affected especially at the high dose level of DEHP. **Singh (1972)** also reported incomplete or missing leg bones. Congenital skeletal deformities (66-96%), with multiple skeletal (14-64%) and appendicular malformations (25-57%) was reported by **Parkie et al (1982)** in Wistar strain rats when treated with a single intraperitoneal injection (0.6 mL/kg) of dimethoxyethyl phthalate (DMEP) on day 10, 11, 12, 13 or 14 of gestation. **Singh (1972)** also reported skeletal abnormalities included twisted hands and legs, elongated and fused ribs (bilateral and unilateral) and incomplete or missing leg bones in rats when treated with eight phthalic acid esters.

DEHP passed across the placenta and reached the fetus. Therefore, humans exposed to sufficiently high level of DEHP during pregnancy could possibly have babies with low birth weights, skeletal and nervous system problems (**ATSDR, 2002**).

5. Conclusion

This work showed that Di(2-ethylhexyl) phthalate causes high percentage of fetal mortality in all treated groups. As well as phthalate causes growth retardation for the fetuses. Haematoma; dark red patches scattered on the different parts of the body of fetuses at 20th day of gestation maternally treated with phthalates. These investigation indicated that most elements of fetuses skeleton showed more or less, complete ossification

Acknowledgments

The student would like to express their gratitude to Prof. Dr: Ragaa, M. El-Balshy; Prof. Dr Seham, A. Ibrahim; Prof. Dr Mohammed, H. Awwad and Dr Amal, A. El- Daly; Faculty of Science Benha University. Since part of this work could not have been done without their helpful support critical discussion.

References

- [1] ATSDR (Agency for Toxic Substances and Disease Registry). (2002): Toxicological profile for di (2-ethylhexyl) phthalate. U.S. Department of Health and Human Services. :pp. 291
- [2] Billet, F. S. and Wild, A. E., (1975): Practical studies of animal development. Printed in G.B. by Wilmer brothers LTD. Birkenhead; 185-303.
- [3] Borch, J.; Ladefoged, O.; Hass, U. and Vinggaard, A.M.(2006): Mechanisms underlying the anti-androgenic effects of diethylhexyl phthalate in fetal Rat testis . Toxicology, 223:144-155.
- [4] Calafat, A.M.; Needham, L.L.; Silva, M.J. and Lambert, G. (2004): Exposure to di-(2-ethylhexyl) phthalate among premature neonates in a neonatal intensive care unit. Pediatrics, 113:429-434.
- [5] Carlson K. R., (2010): Toxicity Review of Di (2-ethylhexyl) phthalate (DEHP). Toxicol, Direct. Health Sci. MD 14:208-317
- [6] Falkeholm, L.; Grant, C.A.; Magnusson, A. and Möller, E. (2006): Xylene-Free Method for Histological Preparation: A Multicentre Evaluation. Lab Invest , 81:1213-1221.
- [7] Foster, P.M. (2006): Disruption of reproductive development in male rat offspring following in utero exposure to phthalate esters Int J Androl , 29(1):140-147.
- [8] Hauser, R.; Calafat, A.M. (2005): Phthalates and human health. Occup Environ Med, 2(11):806-818.
- [9] Holladay, S.D. and Smialowicz, R.J. (2000): Development of the murine and human immune system: differential effects of immunotoxicants depend on time of exposure. Environ. Health Perspect, 108(3): 463-473.
- [10] Kim, E.J.; Kim, J. W. and Lee, S. K. (2004): Inhibition of oocyte development in japanesemedake (Oryzias, Latipes) exposed to di-2- ethylhexyle phthalate. Eviron. Int, 28:359-365.
- [11] Lamb, J.C.; Chapin, R.E.; Teague, J.; Lawton, A.D. and Reel, J.R. (1987): Reproductive effects of four phthalic acid esters in the mouse. Toxicol Appl Pharmacol; 88:255-269.
- [12] Latini, G.; De Felice, C.; Presta, G.; Del Vecchio, A.; Paris, I.; Ruggieri, F. and Mazzeo, P.(2003): In utero exposure to di-(2-ethylhexyl)phthalate and duration of human pregnancy. Environ. Health Perspect, 111:1783-1785.
- [13] Lorz, P. M.; Towae, F. K.; Enke, W.; Jäckh, R.; Bhargava, N. and Hillesheim, W. (2005): "Phthalic Acid and Derivatives", Ullmann's Encyclopedia of Industrial Chemistry, Weinheim: Wiley-VCH, doi: 10.1002/14356007.a20_181.pub2.
- [14] Main, K.M.; Mortensen, M.M.; Kaleva, K.A.; Boisen and Damgaard, I.N.(2006): Human Breast Milk Contamination with Phthalates and Alterations of Endogenous Reproductive Hormones in Infants Three Months of Age. Environ. Health Perspect, 114: 270-276.
- [15] Matsumoto, M.; Hirata-Koizumi, M. and Ema, M. (2008): Potential adverse effects of phthalic acid esters on human health: A review of recent studies on reproduction. Regul. Toxicol. Pharmacol, 50(1):37-49.
- [16] McClain, R. M. and Becker, B. A. (1975): Teratogenicity, fetal toxicity and placental transfer of lead nitrate in rats. Toxicol. App. Pharmacol, 31: 72-82.

- [17] McGee- Russell, S.M.(1958): Alizarin red s method for calcium. . Histochem. Cytochem, 6:22.
- [18] Miura, K.; Jin, J.B.; Lee, J.; Yoo, C.Y.; Stirm, V.; Miura, T.; Ashworth, E.N.; Bressan, R.A.Y.; Un, D.J. and Hasegawa, P.M. (2007): SIZI-mediated sumoylation of ICE1 controls CBF3/DREPIA expression and freezing tolerance in Arabidopsis. Plant cell, 19:1403-1414.
- [19] Mortensen, G. K.; Main, K. M.; Andersson, A.-M.; Leffers, H. and Skakkebæk, N. E. (2005): Determination of phthalate monoesters in human breast milk, consumer milk and infant formula by tandem mass spectrometry (LC/MC/MS). Analytical Bioanalyt. Chemist. 382, 1084–1092.
- [20] Parkie, M.R; Webb, M. and Norcross, M.A. (1982): Dimethoxyethyl phthalate: embryopathy, teratogenicity, fetal metabolism and the role of zinc in the rat. Environ Health Perspect, 45:89–97.
- [21] SCENIHR (Scientific Committee on Emerging and Newly-Identified Health Risks). (2007). Preliminary report on the safety of medical devices containing DEHP-plasticized PVC or other plasticizers on neonates and other groups possibly at risk. Health & Consumer Protection Directorate-General. European Commission, 84pp.
- [22] Shiota, K. and Mima, S.(1985): Assessment of the teratogenicity of di(2-ethyl hexyl) phthalate and mono(2-ethylhexyl) phthalate (DBP) in mice. Arch Toxicol, 56 :263-266.
- [23] Shiota, K. and Nishimura, H. (1982): Teratogenicity of di (2-ethylhexyl) phthalate (DEHP) and di-n-butyl phthalate (DBP) in mice. Environ Health Perspect, 45: 65-70.
- [24] Shiota K.; Chou, M. J. and Nishimura, H. (1980): Embryo toxic effects of di-2-ethylhexyl phthalate (DEHP) in di-n-butyl phthalate (DBP) in mice. Environ. Res., 22: 245-253.
- [25] Singh, A.R; Lawrence, W.H; Autian, J. (1972): Teratogenicity of phthalate esters in rats. J Pharm Sci., 61(1):51–55.
- [26] Sorensen, L. k. (2006): Determination of phthalates in milk and milk products by liquid chromatography/tandem mass spectrometry. Rapid., 20(7):1135-1143.
- [27] Tomita, I.; Nakamura, Y.; Aoki, N. and Inui, N. (1982b): Mutagenic/carcinogenic potential of DEHP and MEHP. Environ Health Perspect., 45:119–125
- [28] Tyl, R.W.; Price, C.J.; Marr, M.C. and Kimmel, C.A. (1988): Developmental toxicity evaluation of dietary di(2-ethylhexyl) phthalate in Fischer 344 rats and CD-1 mice. Fundam. Appl. Toxicol. 10: 395-412.
- [29] Wolkowski-Tyl, R, C.; Jones-Price.; Marr, M.C. and Kimmel, C.A. (1984b): Teratologic evaluation of diethylhexyl phthalate (CAS No. 117-81-7) in CD-1 mice. Gov. Rep. Announce. Index, 85(2): 70.
- [30] Woodward, K.N.; Smith, A.M.; Mariscotti, S.P. and Tomlinson, N.J. (1986): Review of the toxicity of the esters of o-phthalic acid (phthalate esters). Health and Safety Executive, Toxicity Review 14, p: 183.
- [31] Yagi, Y.; Nakamura, Y.; Tomita, I.; Tsuchikawa, K. and Shimoi, N. (1980): Teratogenic potential of di- and mono-(2-ethylhexyl) phthalate in mice. J. Environ. Pathol. Toxicol. 4: 533-544.